



Patient Name: **Last Name ^ First Name**
Date of Birth: **XX-XX-XXXX**
Age: **XX**
Referring Provider: **Last Name ^ First Name**
Image Modality: **CBCT, MRI, Panoramic, and/or Intraoral(s)**
Report Type: **Routine, Pathology, Implant Measurements, Endodontics, Orthodontics, Airway, Impactions, TMJs**
Reason for Scan & Clinical History: **Entered by Dental Practice during scan upload**

Study Date: **XX-XX-XXXX**
Accession Number: **XXXXXXXXXXXX**
Report Date: **XX-XX-XXXX**
Radiologist: **Capture3DR OMR**

Radiographic Findings:

- Paranasal Sinuses - **There is an interruption of the left maxillary sinus floor adjacent to edentulous site #15 and direct communication with the oral cavity.**
- Nasal Cavity - **The septum is mildly deviated to the left. There is concha bullosa of the right middle turbinate with minimal narrowing of the common meatus.**
- Airway - **The oropharynx, velopharynx, and nasopharynx are patent and symmetrical but narrowed with an oropharyngeal airway minimum cross-sectional area of approximately 43 mm².**
- Temporomandibular Joints - **Right and Left TMJ: Both condyles exhibit two distinct depressions on the superior aspects; the cortices of the condyles, articular eminences, and glenoid fossae are intact. Condyles are centered anteroposteriorly within the fossae.**
- Dental - **#17: Impacted with a vertical orientation with the occlusal surface not covered by bone. The crown is in contact with the CEJ of the D root of #18 - no root resorption. The 2 non-fused roots are fully developed; each has 2 apices, each in contact with the adjacent mandibular cortex. The furcal aspects of the apices have the following effects on the morphology of the mandibular canal: loss of cortication, 50% compression of the luminal cross-sectional area, and mild deviation of the location. There is no external resorption.**
#31: Endodontically-treated with 2 roots and 3 canals obturated. Filling material in the M root canals ends at the root outline of the mild-to-moderately resorbed apex – there is a well-defined, 5mm x 5mm x 5mm soft-tissue density, periapical lesion in close proximity to the superior cortical margin of the mandibular canal. No missed canals detected.
- Implants - **Implant site #4: There is no implant guide. Trabecular bone pattern is radiographically within the range of normal. In the centerline of the site, measurements of the alveolar crest width and alveolar ridge height inferior to the maxillary sinus floor are as indicated in the images below.**
- Osseous Structures - **There are large bilateral lingual mandibular tori with intact cortices.**

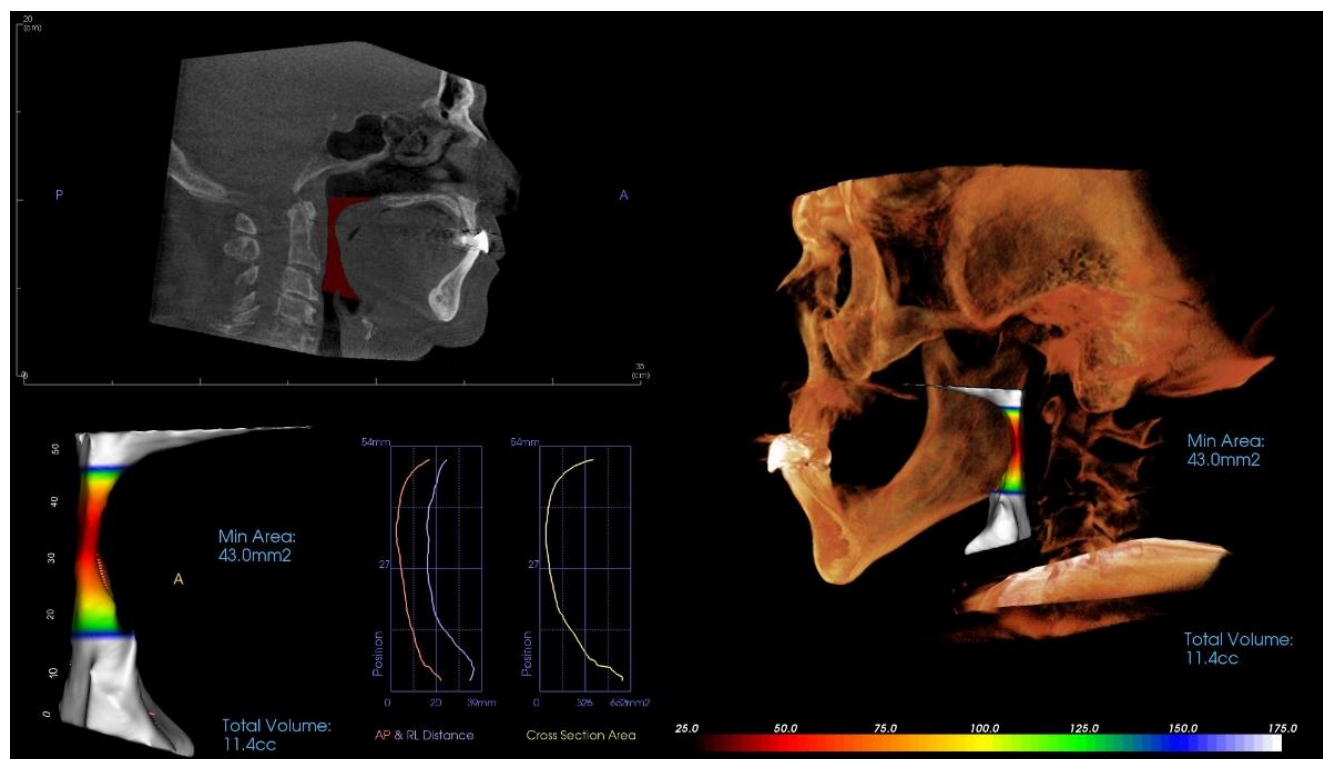
Impressions:

- **Left maxillary sinus:** Oroantral communication – correlate with clinical history & findings. Recommend follow-up noting surgical correction likely required due to size and lack of soft tissue compensation.
- **Airway:** Oropharyngeal airway minimum cross-sectional area is below the range of normal. Note this may correlate with an increased risk for obstructive sleep-disordered breathing.
- **Right and Left Temporomandibular Joints:** Negative for osseous pathosis noting trifold character of the condyles, a variant of normal.
- **Implant site #4:** Negative for radiographic evidence of osseous pathosis that would preclude implant placement. Note that while there appears to be adequate bone, without a surgical guide, no specific assessment is possible.
- **#17:** Vertical impaction; mandibular canal is moderately altered by apical ends of roots; negative for pericoronal pathosis.
- **#31:** Previously treated; persistent apical periodontitis.

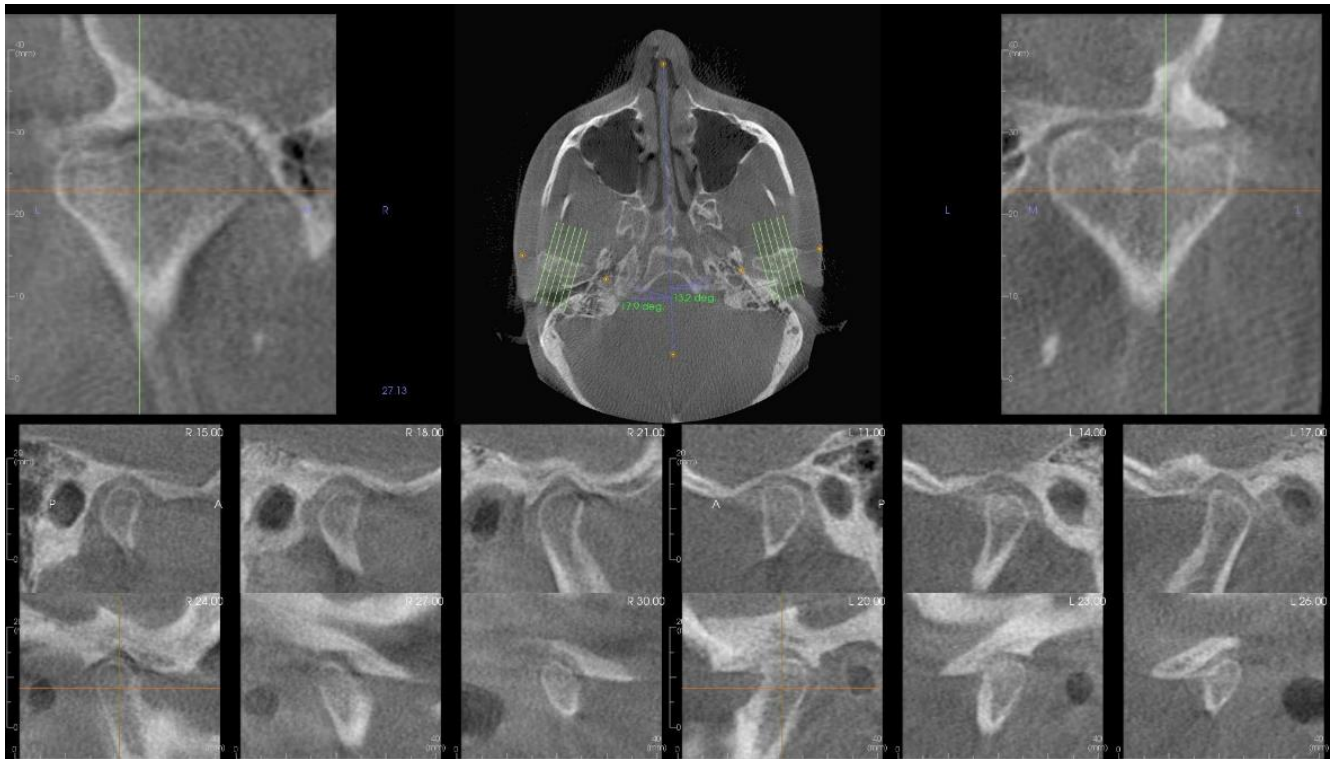
I hereby attest that the information contained in this report dated XX-XX-XX accurately reflects the conclusions that I made in my capacity as the interpreting Oral & Maxillofacial Radiologist.

Signed by Last Name, First Name

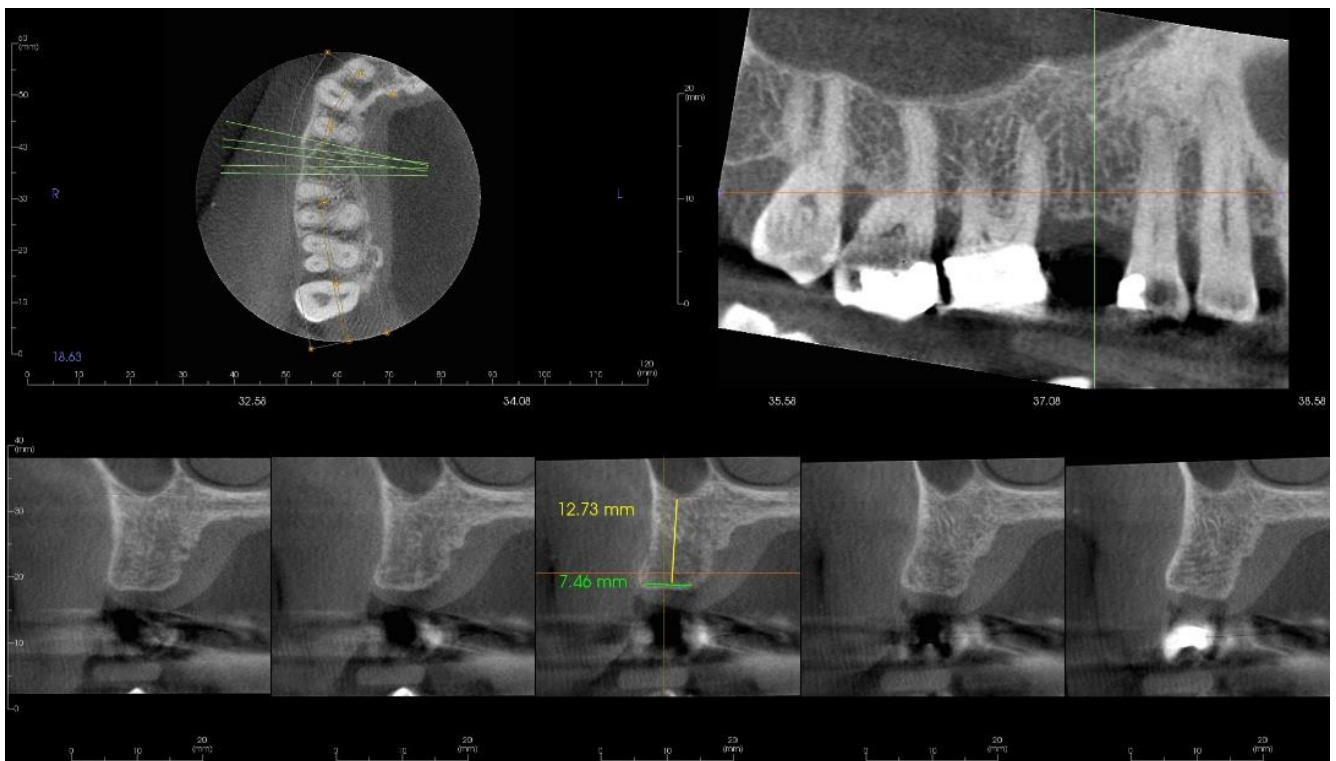
Electronically Approved Date XX-XX-XXXX



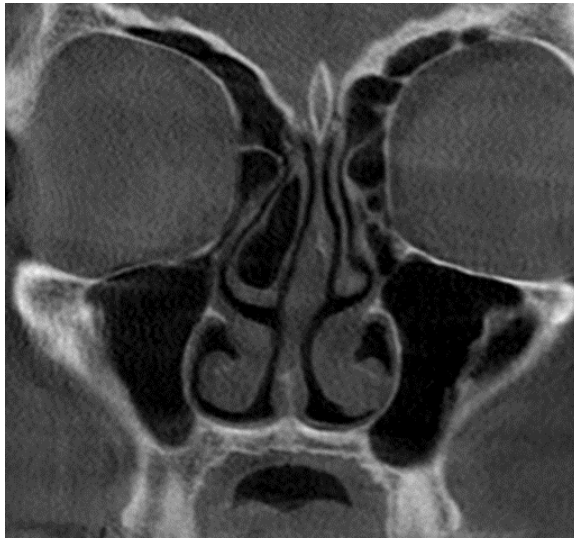Airway Analysis



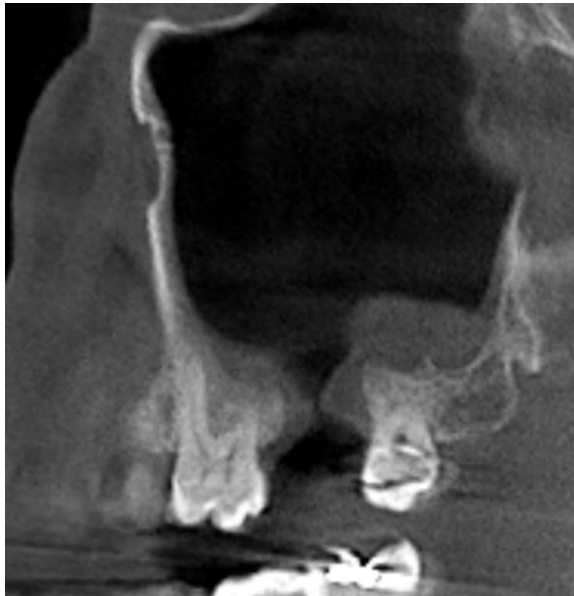Temporomandibular Joint Analysis



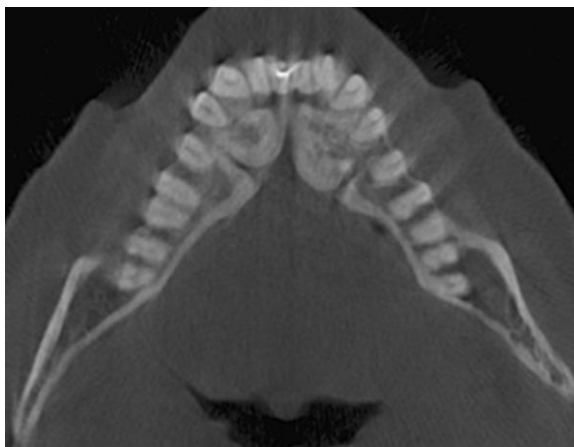Implant Site #4: 1.5 mm increments between cross-sections



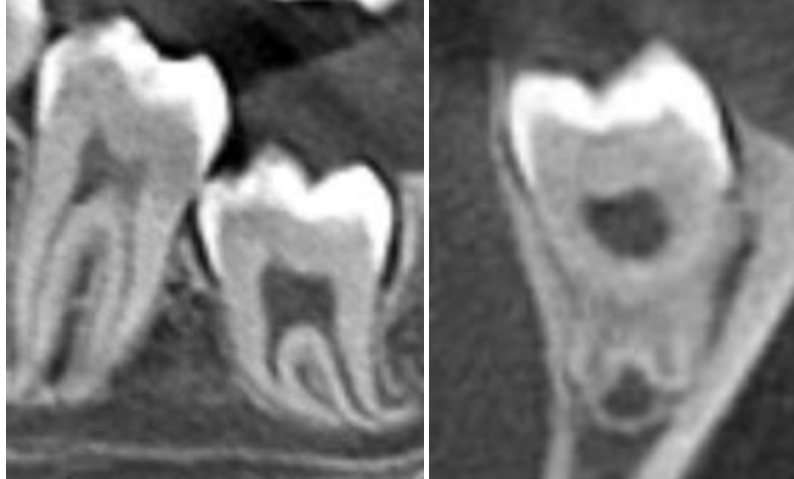
Coronal View of Nasal Cavity and Paranasal Sinuses



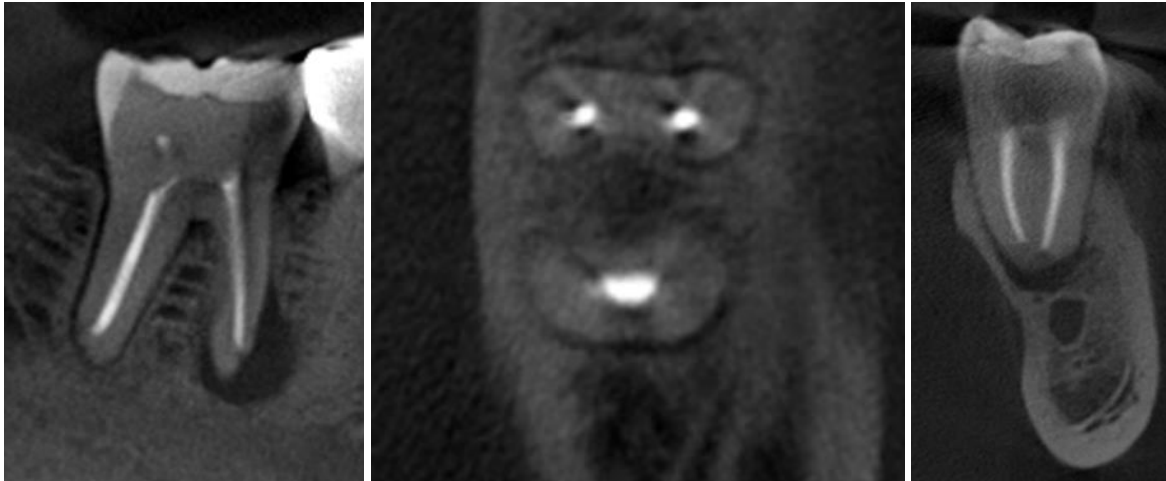Sagittal View of Left Maxillary Sinus



Axial View of Mandible



#17: Sagittal and Coronal Views



#31: Sagittal, Axial, and Coronal Views

PRIVILEGED AND CONFIDENTIAL: This report and the information contained herein are confidential and protected from disclosure pursuant to Federal law. This message is intended only for the use of the Addressee(s) and may contain information that is PRIVILEGED and CONFIDENTIAL. If you are not the intended recipient, you are hereby notified that the use, dissemination, or copying of this information is strictly prohibited. If you have received this communication in error, please erase all copies of the message and its attachments and notify the sender immediately.